



# ORTHOPEDECS & SPORTS MEDICINE BAYCARE CLINIC

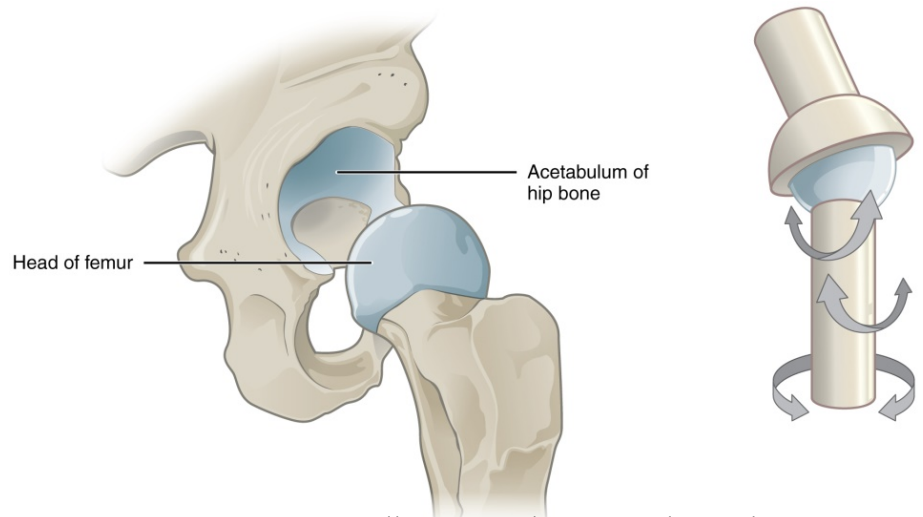
## Hip Anatomy

The hip is considered a “ball and socket” joint. With proper anatomy, the joint moves freely with good stability in all directions. The hip joint is made up of the femoral head (ball), the acetabulum (socket) and supporting structures.

Surrounding the acetabulum is a “gasket like” ring of fibrocartilage called the labrum. The labrum helps provide stability to the ball within the socket but more importantly has a sealing effect keeping fluid and pressure within

the joint and optimizing joint lubrication. Articular cartilage is the “teflon like” low friction surface layer on the femoral head and acetabulum. Loss of articular cartilage leads to degenerative arthritis.

Sometimes individuals are born with or later develop an abnormal shape of the hip joint that can lead to different types of hip problems. The most common form is femoral acetabular impingement (FAI). The reason that this occurs is not clearly understood, and symptoms from these hip disorders can arise at various stages of life.



<http://philschatz.com/anatomy-book/contents/m46383.html>

## Femoral Acetabular Impingement/FAI

There are two main categories of FAI related to bony structure of the hip joint: cam and pincer.

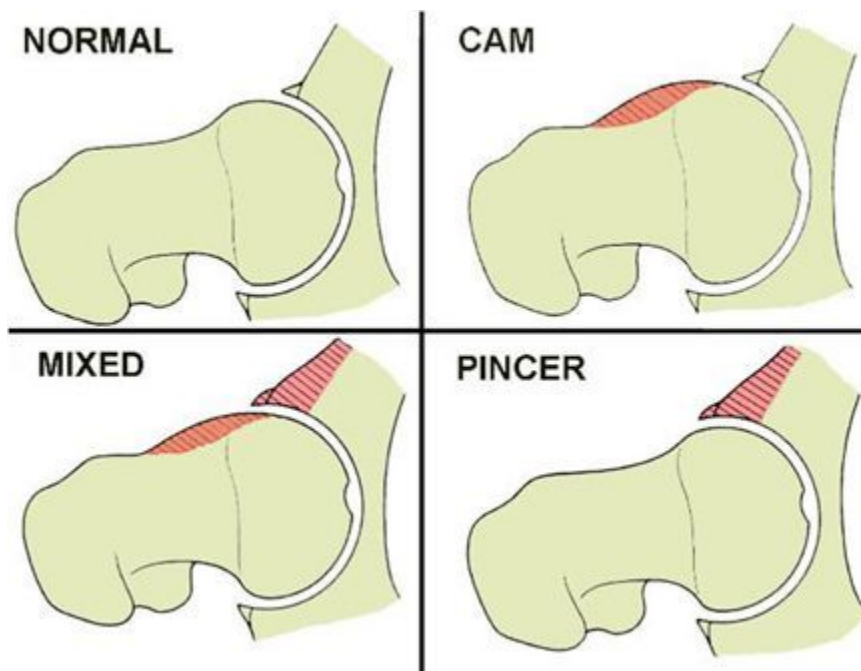
**Cam deformity** - This form of FAI occurs when the shape of the femoral head is oblong instead of round. The bony prominence on the outer aspect of the femoral head bumps against the rim of the socket at a certain degree of hip flexion and rotation, causing excessive shear stress on the articular cartilage and eventually leading to articular cartilage damage.

**Pincer deformity** - This form of impingement occurs when the acetabulum is deeper than normal or has excessive bony coverage on its upper-outer rim. This bony prominence acts as a block against the femoral head as the hip is flexed and



# ORTHOPEDECS & SPORTS MEDICINE BAYCARE CLINIC

rotated. Abnormal contact then occurs between the ball and socket repetitively pinching the labrum over time and eventually causing the labrum to tear.

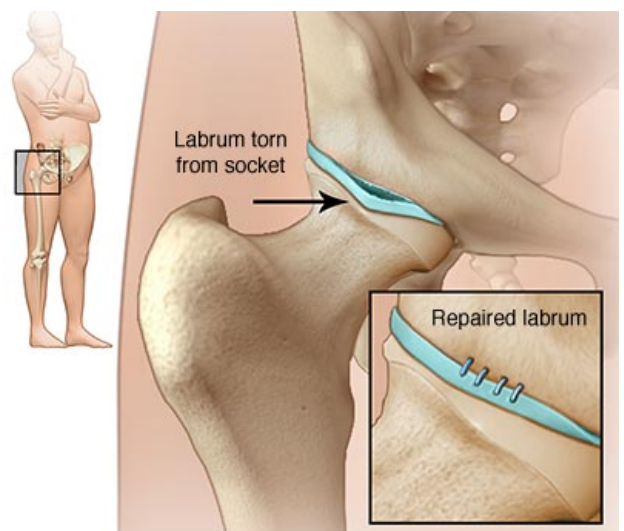


<http://clinicalgate.com/56-hip-labral-tears/>

*Coxa Profunda* – This is a term describes an acetabulum deeper than normal. This essentially creates a pincer like impingement.

*Mixed deformity* – This form of impingement occurs when both cam and pincer FAI are present. The resultant symptoms are often more severe and/or present earlier in life compared to singular forms of FAI.

FAI causes repetitive micro-trauma to the hip joint which over time--and often without specific injury--leads to structural damage, most commonly: labral tears, articular cartilage damage, ligament tears, and/or loose cartilage fragments. Normally symptoms occur with the onset of structural damage. Mechanical symptoms, such as sharp pain, painful catching or locking, or sense of giving way should raise concern for an





# ORTHOPEDICS & SPORTS MEDICINE

BAYCARE CLINIC

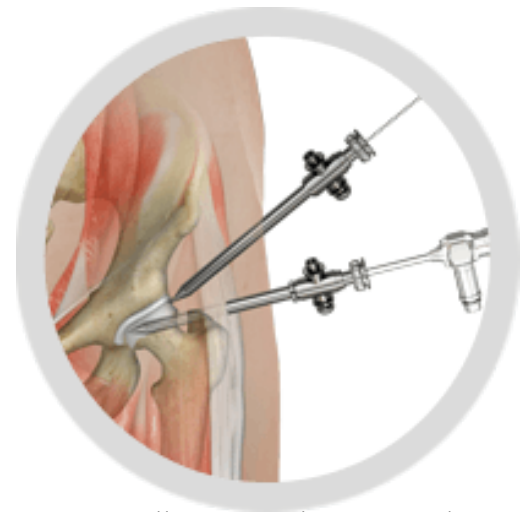
unstable structural problem of the hip joint, which then warrants specialized evaluation to determine the underlying cause. A review of symptoms, physical examination, x-ray and MRI imaging are used in the diagnostic process. Treatment options can be discussed and determined once the diagnosis is confirmed.

## Hip Arthroscopy (Hip Scope)

Hip arthroscopy is a surgical procedure where an orthopedic surgeon will use a camera (scope) to see inside and around the hip joint. The camera is placed through 2-3 small cuts (portals) made into the skin. One portal is occupied by the camera and the other portals are used for tools and instruments. The camera allows the surgeon to see all the structures within the hip joint. The same procedure can also be used to visualize the side of the hip (trochanteric space) and behind the hip (sub-gluteal space).

Hip arthroscopy allows the surgeon to perform various procedures within and around the hip joint depending on the underlying problem. For FAI, the abnormal bony structure is re-shaped to restore a proper fit between the ball and socket, and the related structure damage is repaired.

A hip arthroscopy is a form of hip preservation surgery, meaning that the treatment is intended to fix the underlying structural problem and restore optimal joint health and function. This may slow the progression of degenerative arthritis, though a hip scope does not fix arthritis or completely stop arthritis from developing later in life.



<http://www.kbjs.com/hip-arthroscopy/>

When to perform a Hip Arthroscopy? The decision for surgery is based not just on an X-ray or MRI findings, but rather on severity of symptoms and the effect the symptoms have on the individual's quality of life.

### *Common indications for Hip Arthroscopy:*

- Hip pain due to FAI
- Torn labrum or ligament
- Loose bone or cartilage in the hip joint

### *Other Indications for Hip Arthroscopy:*

- Hip Abductor tendon tears
- Hip flexor tendon problems

- Piriformis syndrome/Sciatic nerve entrapment
- Problems related to hip dysplasia

### *Contraindications for Hip Arthroscopy:*

- Arthritis
- Severe hip dysplasia
- Uncertain source of pain or suspected non-structural source of pain